

A Case of Renal Pelvi-venous Fistula Diagnosed by Nephrostogram: A Rare Complication of Percutaneous Nephrostomy

VISHAL NANDKISHOR BAKARE¹, RITESH KUMAR SAHU²,
ROHAN RAHUL THAKUR³, ANIKETH DAVANGERE HIREMATH⁴



ABSTRACT

Percutaneous Nephrostomy (PCN) is a minimally invasive procedure used in patients with hydronephrosis. Major haemorrhagic complications requiring transfusions occur in 1-4% of PCNs, while major vascular injuries (requiring embolisation or nephrectomy) occur in 0.1-1% of cases. The sources of bleeding are usually from pseudoaneurysms or Arteriovenous (AV) fistulas when the nephrostomy tract passes near the renal hilum. A calyceal-venous or renal pelvi-venous fistula is a rare but significant complication that can arise following PCN, ureteric obstruction, and renal transplantation. Invasive treatment options for managing these fistulae include transvenous embolisation, external drainage to relieve outflow obstruction, and open surgical management, which may involve closure of the fistula, partial nephrectomy, or complete nephrectomy. Hereby, the authors present a case of 74-year-old male patient with carcinoma of the urinary bladder, who had a history of bilateral PCN due to vesico-ureteric junction involvement. He presented post-procedure with continuous haematuria from the left PCN catheter. There was a significant drop in haemoglobin; however, the patient remained vitally stable. A nephrostogram performed by injecting contrast via the PCN catheter revealed a renal pelvis-renal vein (pelvi-venous) fistula. He was managed by placing a pigtail catheter with its tip in the mid-ureter to provide external drainage and a tamponade effect at the fistula site. The haematuria gradually resolved within two days, with clear urine output. Therefore, the authors aimed to draw attention to the rare finding of a renal pelvi-venous fistula on nephrostogram following PCN and its management through the repositioning of the nephrostomy tube.

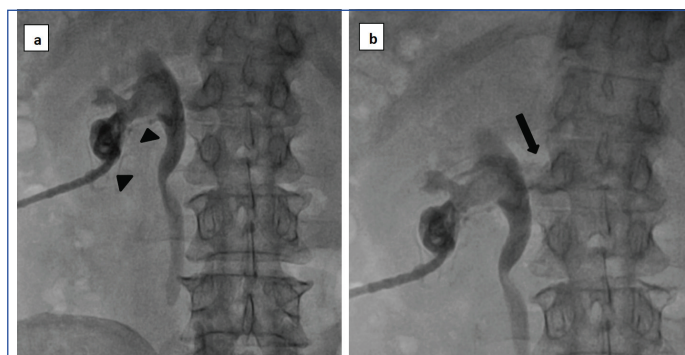
Keywords: Carcinoma, Embolisation, Haematuria, Nephrectomy, Pigtail catheter, Postoperative complication

CASE REPORT

A 74-year-old male patient presented to the Outpatient Department (OPD) with a known case of carcinoma of the urinary bladder, diagnosed 15 days prior. He had a history of bilateral PCN performed one day earlier for vesico-ureteric junction involvement, which caused bilateral hydronephrosis. Post-procedure, he developed continuous haematuria from the left PCN catheter and was referred to present Institute for further management after two hours of unsuccessful conservative treatment. Initial evaluation revealed hypotension and tachycardia [Blood Pressure (BP): 90/60 mmHg and heart rate of 110 beats per minute (bpm)]. Investigations indicated a significant drop in Haemoglobin level (Hb: 6.5 gm/dL), and he was subsequently treated with blood transfusions.

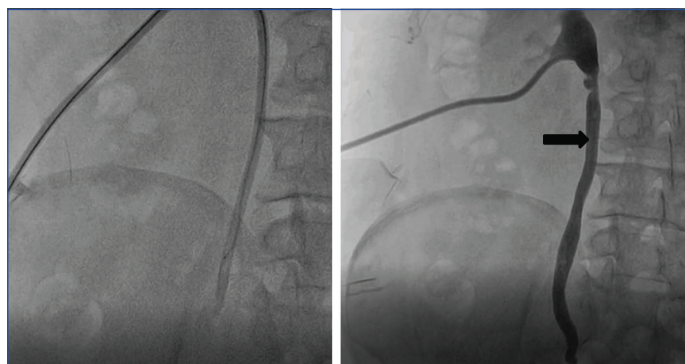Transarterial renal angiography did not reveal any pseudoaneurysms or AV fistulas. Subsequently, a nephrostogram was performed by injecting contrast via the PCN catheter into the renal pelvi-calyceal system [Table/Fig-1a,b]. A loop of the pigtail catheter was noted in the inferior calyx. Contrast opacification of the renal pelvis was followed by the opacification of small draining veins at the level of the lower pole calyx, which was likely the site of a fistulous communication. The main left Renal Vein (RV) and Inferior Vena Cava (IVC) were also sequentially opacified. This finding suggested a fistulous communication between the renal pelvi-calyceal system and the draining veins.

Over the metallic guide wire access, the pigtail drainage catheter was placed with its hole-bearing part and tip in the mid ureter to achieve a tamponade effect of the catheter at the fistulous site in the inferior calyx [Table/Fig-2]. In the postoperative period, the patient was closely monitored for vital signs, haemoglobin levels, and the presence of haematuria. He remained vitally stable with no further drop in haemoglobin levels. The haematuria gradually resolved within two days, resulting in clear urine output. A urine routine and



[Table/Fig-1]: Nephrostogram via left PCN catheter showing: a) opacification of small draining veins (arrowheads) at the level of lower pole calyx; followed by; b) opacification of left renal vein (arrow) and IVC.

microscopy were performed on postoperative day 7, which did not reveal the presence of Red Blood Cells (RBCs) in the urine. There were no adverse events or further complications during the follow-up period.



[Table/Fig-2]: Post-procedure nephrostogram showing pigtail drainage catheter with its tip in the mid ureter (arrow).

DISCUSSION

The placement of a PCN is a minimally invasive procedure that can be temporary or permanent in patients with hydronephrosis. Indications for the procedure include urinary drainage in cases of failed transurethral access, pyonephrosis, access for percutaneous nephrolithotomy, and urinary diversion in the setting of a urinary leak or fistula [1].

Despite being a minimally invasive technique, it may involve minor complications Such as Urinary Tract Infections (UTI), catheter dislodgement, catheter obstruction due to debris, urine leak, and skin inflammation at the site of the PCN catheter. Major complications are uncommon and include cardiac arrest, bleeding requiring transfusion or embolisation, sepsis, hydrothorax, or pneumothorax [2]. Major haemorrhagic complications requiring transfusions occur in 1-4% of PCN cases, and major vascular injuries (requiring embolisation or nephrectomy) occur in 0.1-1% of cases [3].

Sources of bleeding following PCN may include parenchymal injury from the nephrostomy tract itself, lacerations during tract dilation, and vascular injuries. Vascular injuries are rare but may lead to late bleeding complications upto three weeks after the procedure. They generally originate from pseudoaneurysms or AV fistulas and require therapeutic interventions [4]. These vascular injuries usually occur when the nephrostomy tract passes near the renal hilum, causing laceration of the interlobar and lower pole arteries [5].

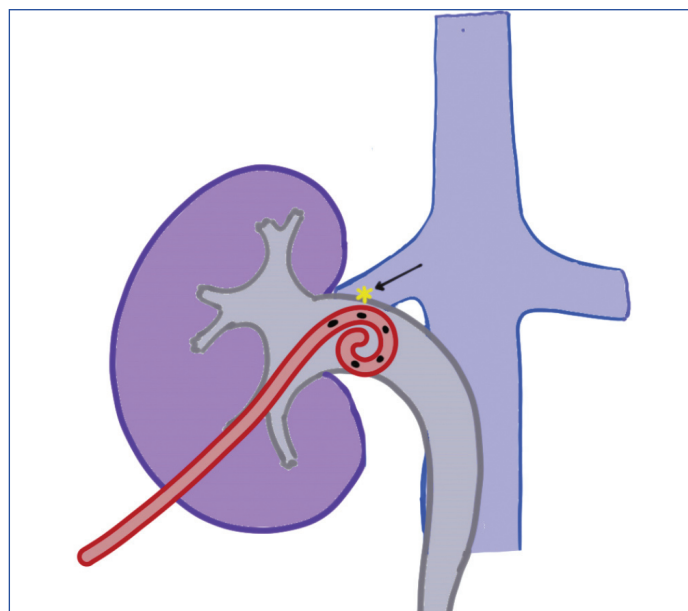
Renal pelvi-venous fistulae have been reported in the literature as rare complications following percutaneous nephrolithotomy, ureteric obstruction, renal transplantation, or as a non traumatic occurrence due to chronic outflow obstruction [6-9]. Treatment options include transvenous embolisation [7], external drainage to relieve outflow obstruction [9], and open surgical management [10,11], which may involve closure of the fistula, partial nephrectomy, or complete nephrectomy. Rastogi N et al., reported a case of coexisting intrarenal AV and calyceo-venous fistulae after percutaneous nephrolithotomy, successfully managed with embolisation of the intrarenal Arteriovenous Fistula (AVF) and conservative management of the calyceo-venous fistula [12]. Management of present rare condition should be case-based and depends on the discretion of the physician and interventionist, due to limited evidence supporting any particular treatment method.

In present case, the patient presented with delayed haematuria and a drop in haemoglobin as an iatrogenic complication of PCN. The usual suspects of renal artery pseudoaneurysm and renal AVF were first ruled out. A nephrostogram then revealed the presence of a renal pelvi-venous fistula, which was successfully managed conservatively. In this relatively stable patient with a urinary tract malignancy, authors chose conservative management with the intention of minimising invasive procedures and preserving renal function. Open surgical treatment can be considered a second-line option in case of non resolution, with partial nephrectomy if the site of the fistula can be clearly localised on preoperative imaging, or total nephrectomy in the event of treatment failure or renal venous thrombosis [10].

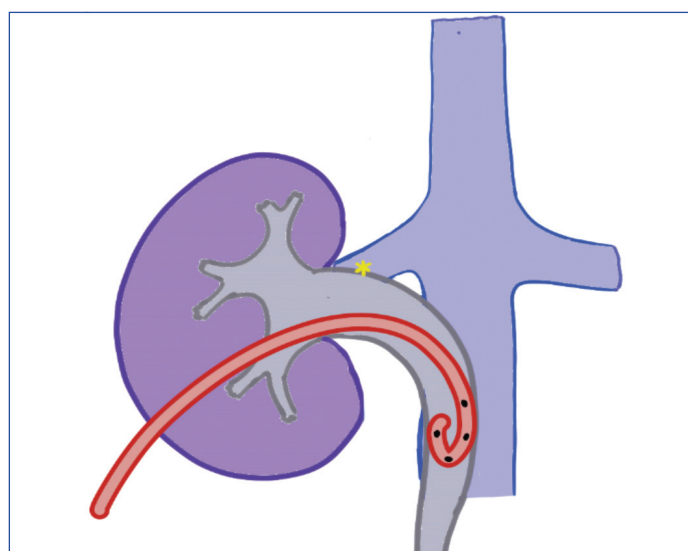
The pigtail catheter was initially positioned with its hole-bearing tip adjacent to the fistulous site, allowing free access for blood extravasation into the drainage catheter has been depicted in [Table/Fig-3]. Authors repositioned the catheter so that the hole-bearing tip was deep inside the mid-ureter, with its non hole bearing portion providing a tamponade effect at the fistulous site, resulting in the formation of a blood clot at that site and resolution of haematuria [Table/Fig-4].

CONCLUSION(S)

Renal pelvi-venous fistulae are abnormal communications between the pelvi-calyceal system and the venous system. They are very rare complications that can arise following chronic ureteral obstruction or may be of iatrogenic origin. Management options



[Table/Fig-3]: Schematic diagram showing initial position of PCN catheter with hole bearing tip in the pelvicalyceal system, adjacent to fistulous site (black arrow).



[Table/Fig-4]: Schematic diagram showing corrected position of PCN catheter with hole bearing tip in the mid ureter, with non hole bearing part adjacent to fistulous site, resulting in tamponade effect eventually closing the fistula.

include transvenous embolisation or an open surgical approach. Based on present case, an alternative approach of conservative management with continued external drainage and the tamponade effect produced by a repositioned PCN catheter may be feasible in haemodynamically stable patients, allowing for spontaneous healing of the renal pelvi-venous fistula.

REFERENCES

- [1] Young M, Leslie SW. Percutaneous Nephrostomy. [Updated 2023 Jun 26]. In: StatPearls [Internet]. Treasure Island (FL): StatPearls Publishing; 2024 Jan-. Available from: <https://www.ncbi.nlm.nih.gov/books/NBK493205/>.
- [2] Radecka E, Magnusson A. Complications associated with percutaneous nephrostomies. A retrospective study. *Acta Radiologica*. 2004;45(2):184-88.
- [3] Ramchandani P, Cardella JF, Grassi CJ, Roberts AC, Sacks D, Schwartzberg MS, et al; Society of Interventional Radiology Standards of Practice Committee. Quality improvement guidelines for percutaneous nephrostomy. *J Vasc Interv Radiol*. 2003;14(9 Pt 2):S277-81.
- [4] Michel MS, Trojan L, Rassweiler JJ. Complications in percutaneous nephrolithotomy. *Eur Urol*. 2007;51(4):899-906.
- [5] Esparaz AM, Pearl JA, Herts BR, LeBlanc J, Kapoor B. Iatrogenic urinary tract injuries: Etiology, diagnosis, and management. *Semin Intervent Radiol*. 2015;32(02):195-208.
- [6] Low LS, Nair SM, Wu L, Lanka L, Devcich GA. Calyceal-venous fistula of the kidney: A rare case report and review of literature. *Urol Case Rep*. 2018;23:23-24.
- [7] Venyo AK, Shah S. Lower polar aberrant renal vein-renal pelvis fistula: A rare cause of haematuria. *West Afr J Med*. 2008;27(4):267-70.
- [8] Weigel JD, Egal M, Bakker J. Fatal calyceal-venous fistula. *Intensive Care Medicine*. 2016;42:1805.

[9]

Chan YH, Wong KM, Kwok PC, Liu AY, Choi KS, Chau KF, et al. A veno-caliceal fistula related to ureteric stricture in a kidney allograft masquerading as renal failure. *Am J Kidney Dis.* 2007;49(4):547-51.

[10]

Mellouki A, Morrone A, Haider R, Chevallier D, Ahallal Y, Durand M. A rare bird spotted: Inferior Vena cava-calyceal fistula on pelvic kidney following an iatrogenic injury during a retrograde intrarenal surgery. *J Clin Images Med Case Rep.* 2022;3(3):1745.

[11]

Al Turki M, Onuora VC, Koko AH, Al Mosa M, Al Jawini N. Pyelovenous fistula: An uncommon cause of 'essential haematuria'. *Urol Int.* 1998;60(3):189-90.

[12]

Rastogi N, Zawacki W, Alencar H. Coexisting intrarenal arteriovenous and caliceovenous fistulae after percutaneous nephrolithotomy: Case report and literature review. *Interv Med Appl Sci.* 2013;5(2):81-84.

PARTICULARS OF CONTRIBUTORS:

1. Assistant Professor, Department of Interventional Radiology, Dr. D. Y. Patil Medical College, Hospital and Research Centre, Pimpri, Pune, Maharashtra, India.
2. Senior Resident, Department of Interventional Radiology, Dr. D. Y. Patil Medical College, Hospital and Research Centre, Pimpri, Pune, Maharashtra, India.
3. Senior Resident, Department of Interventional Radiology, Dr. D. Y. Patil Medical College, Hospital and Research Centre, Pimpri, Pune, Maharashtra, India.
4. Senior Resident, Department of Interventional Radiology, Dr. D. Y. Patil Medical College, Hospital and Research Centre, Pimpri, Pune, Maharashtra, India.

NAME, ADDRESS, E-MAIL ID OF THE CORRESPONDING AUTHOR:

Dr. Rohan Rahul Thakur,
Senior Resident, Department of Interventional Radiology, Dr. D. Y. Patil Medical College,
Pimpri, Pune-411018, Maharashtra, India.
E-mail: rohan.thakurdr@gmail.com

PLAGIARISM CHECKING METHODS: [\[Jain H et al.\]](#)

- Plagiarism X-checker: Sep 30, 2024
- Manual Googling: Nov 28, 2024
- iThenticate Software: Nov 30, 2024 (5%)

ETYMOLOGY: Author Origin

EMENDATIONS: 6

AUTHOR DECLARATION:

- Financial or Other Competing Interests: None
- Was informed consent obtained from the subjects involved in the study? Yes
- For any images presented appropriate consent has been obtained from the subjects. Yes

Date of Submission: [Sep 28, 2024](#)
Date of Peer Review: [Oct 17, 2024](#)
Date of Acceptance: [Dec 03, 2024](#)
Date of Publishing: [Jan 01, 2025](#)